

Platelet-Rich Plasma Combined with Fractional Laser Therapy for Skin Rejuvenation

MIN-KYUNG SHIN, MD, PHD,* JONG-HO LEE, MD,* SANG-JUN LEE, MD, PHD,†
AND NACK-IN KIM, MD, PHD*

BACKGROUND AND OBJECTIVES Platelet-rich plasma (PRP) is an autologous concentration of human platelets contained in a small volume of plasma and has recently been shown to accelerate wound healing and rejuvenate aging skin. The current study was conducted to determine whether there are additional effects of PRP combined with fractional laser therapy.

MATERIALS AND METHODS Twenty-two Korean women underwent three sessions of fractional laser; 11 were treated with topical application of PRP combined with fractional laser. Evaluations were done at baseline and 1 month after the final treatment. The outcome assessments included subjective satisfaction scale; blinded clinical assessment; and the biophysical parameters of roughness, elasticity, skin hydration, and the erythema and melanin index. Biopsies were analyzed using hematoxylin and eosin, Masson-trichrome, and immunohistochemistry for matrix metalloproteinase-1.

RESULTS PRP combined with fractional laser increased subject satisfaction and skin elasticity and decreased the erythema index. PRP increased the length of the dermoepidermal junction, the amount of collagen, and the number of fibroblasts.

CONCLUSION PRP with fractional laser treatment is a good combination therapy for skin rejuvenation. Keratinocyte and fibroblast proliferation and collagen production can explain the capacity of PRP to increase dermal elasticity.

The authors have indicated no significant interest with commercial supporters.

Platelet-rich plasma (PRP) is an autologous concentration of human platelets contained in a small volume of plasma. PRP has been used over the last several years as an effective treatment in various surgical and medical fields. In the field of dermatology, PRP has proven successful for accelerating wound healing. The use of PRP has recently been applied to aesthetic medicine, but there are few studies on the rejuvenation effects of PRP.^{1,2} PRP contains significant amounts of platelet-derived growth factor, transforming growth factor, vascular endothelial growth factor, epidermal growth factor, and fibroblast growth factor^{3,4} and has been shown to enhance early healing through the release of growth factors. One study using

topical growth factors demonstrated that growth factors resulted in smoother skin with less-visible wrinkles.⁵

Nonablative fractional laser provides good clinical outcomes for the treatment of aging skin but has poorer clinical efficacy than ablative laser devices. Fractional laser skin resurfacing may cause adverse reactions such as erythema, acne, milia, infection, and scarring.⁶ Fractional photothermolysis generates microthermal treatment zones (MTZs) in the dermis, which can increase the absorption of PRP when PRP is topically applied.

The objective of this study was to determine whether the combination of nonablative fractional

*Department of Dermatology, College of Medicine, Kyung Hee University; †Arumdaun Nara Dermatologic Clinic, Seoul, Korea

laser and PRP can increase the treatment effect and reduce the adverse reactions.

Subjects, Materials, and Methods

Subjects and Study Design

This was a single-center prospective pilot study. All subjects provided written informed consent, and the local ethics committee approved the protocol in accordance with the principles of Good Clinical Practice and the Declaration of Helsinki.

Twenty-two women (mean age 43.7 ± 6.0 , range: 30–56, skin phototypes IV–V) were enrolled in the study. Subjects were randomly assigned to receive combined PRP and fractional laser treatment or fractional laser treatment alone.

Exclusion criteria were concomitant treatments (other than topical therapy) of the involved skin areas; a history of keloid scarring; isotretinoin use within 1 year of study enrollment; photosensitivity or immune suppression; treatment with other skin rejuvenation techniques such as chemical peeling, botulinum toxin, injectable fillers, and laser skin resurfacing in the previous year; and use of cosmeceuticals containing retinoids, vitamin C, or copper peptides, which could influence collagen synthesis.

Eligible subjects underwent three sessions of fractional laser at 4-week intervals. The outcome assessments included the subjective satisfaction scale, improvement score according to blinded investigators (using standardized photography), biophysical measurements, and skin biopsies. Measurements were conducted before the first treatment and 1 month after the last treatment session. Subjects who did not use cosmeceuticals containing retinol, retinoids, alpha or beta hydroxyl acids, or peptides were enrolled. Subjects were permitted to apply their usual skin care products throughout the study. It was requested that subjects not alter their usual skincare routine during the study period.

Preparation of the PRP

A 12-mL blood sample was drawn and collected in a sterile tube containing 1 mL of citrate phosphate dextrose adenin solution. The tubes were then centrifuged at 3,000 revolutions per minute (rpm) for 5 minutes. The blood samples were separated by centrifugation to obtain two parts of the plasma; the upper part consisted of 3 mL of platelet-poor plasma (PPP) and the lower part consisted of 3 mL of PRP. The 3 mL of PPP was first gently aspirated to avoid mixing it with the PRP. Then the PPP was centrifuged again at 3,000 rpm for 5 minutes. The residual 3 mL of PRP was subsequently aspirated from each test tube and prepared for activation by adding calcium chloride (0.1 mL per 0.9 mL of PRP) to obtain a 3-mL concentration of activated PRP. Topical anesthetic (EMLA cream, Astra, Westborough, MA) was applied for 30 minutes before treatment and then completely removed. A 1,550-nm fractional erbium glass laser (MOSAIC, Lutronic Corporation, Gyeonggi, Korea) was used for the fractional laser treatment. We used the static mode (40 mJ, 50 spots/cm²) and one pass. Three milliliter of the PRP was applied topically and occluded on the full face for 20 minutes.

Outcome Measures

Subjective Satisfaction Scale Subjects completed a self-assessment questionnaire and rated their improvement on a scale from 0 (aggravated) to 4 (much improved). The investigator subjectively graded erythema after treatment on a scale from 0 to 4 (0 = absent, 1 = trace, 2 = slight, 3 = moderate, 4 = prominent). The duration of erythema was investigated through interviews. After treatment, subjects were asked to grade their intraprocedure pain on a visual analog scale from 0 to 4 (0 = no pain, 4 = severe pain). Pain scores and any adverse events and complications were recorded at the time of each treatment and at the follow-up visit. The number of subjects who reported adverse effects at least once during the four visits was determined.

Blinded Clinical Assessment Standardized photographs were obtained at baseline and 1 month after the last treatment. Photographic documentation was performed using identical camera settings and lighting and the same positioning with the same camera (Canon EOS-40D, 10.1 megapixels, high-resolution setting, 2816×1880 , Canon Corp., Tokyo, Japan). Two dermatologists who were blinded to subject treatment group evaluated the serial photographs in a randomized fashion (before and after treatment, without labeling) to determine whether discernible clinical improvement had occurred. If a particular masked reviewer detected a change, the reviewer was asked to identify the posttreatment image. If the correct image was identified as the posttreatment image, the assessment from the reviewer was considered an improvement (a score of 1 point); if the reviewer identified the wrong image as the post-treatment image, the assessment from the reviewer was considered as worsening (a score of -1 point). If the reviewer reported no difference between the two photographs, the assessment was considered to be indicative of no change (a score of 0 points). The sum of the assessment scores was calculated as the improvement score.

Biophysical Evaluations All measurements were taken after subjects had undergone an acclimatization period of at least 20 minutes in an air conditioned room under standardized conditions ($22-25^{\circ}\text{C}$, 50% humidity). The parameters assessed were in vivo skin surface roughness, elasticity, hydration, erythema, and the melanin index. Each measurement was performed on the left and right cheeks of each subject. Percentage improvement was calculated as $(\text{final value} - \text{baseline value}) / \text{baseline value} \times 100$.

Skin Surface Roughness A camera (Visioscan VC 98; Courage & Khazaka Electronic GmbH, Cologne, Germany) with a high-resolution black-and-white video sensor and an ultraviolet A light source built into it to illuminate the skin was used to measure the skin surface roughness. Based on

the gray-level distribution of the image produced, computer software was used to quantify skin surface roughness. The roughness parameter investigated in this study was R3. R3 is the average of the roughness of different segment from five successive measurements of the same length and is regarded as the most useful parameter for measuring skin wrinkles.⁷

Elasticity Elasticity was determined using a commercially available noninvasive suction skin elasticity meter (Cutometer MPA 580; Courage & Khazaka Electronic GmbH) that created negative pressure and drew the skin into the aperture of the probe. Penetration depth is determined using a noncontact optical measuring system in which the light intensity varies according to the depth of penetration of the skin. The ability of the skin to return to its original position is displayed as a curve, which is translated into a measure of overall elasticity (R2) using standard computer software.^{8,9} The closer the value is to 1, the more elastic is the skin.^{10,11}

Corneometer The skin hydration levels of the facial skin on the cheek were measured in triplicate using a skin capacitance measuring device (Corneometer 820PC; Courage & Khazaka Electronic GmbH). This device can quantify the humidity levels of the stratum corneum based on the distinct dielectric constant of the water.¹²

Erythema and Melanin Index Skin erythema and pigmentation were measured using a reflectance spectrophotometer (Derma-Spectrophotometer, Cortex Technology, Hadsund, Denmark), a narrow-band spectrophotometer designed to measure specific colors caused by two major chromophores (hemoglobin and melanin). The light sources are two light-emitting diodes with selected narrow bands of emitted wavelengths. The peaks of the two bands are centered at 568 nm (green light) and 655 nm (red light); the diodes emit light in sequence, and the reflected light from the skin is detected with a photodetector. After conversion

into a digital form with a built-in microcomputer, the reflectance in the two bands is transformed into an erythema index (E-index) and a melanin index (M-index).

Histologic Analysis

In six subjects, skin biopsies were obtained from the lateral cheek for histologic evaluation at baseline and 1 month after the final PRP treatment. We obtained three randomly chosen histologic photographs per subjects, therefore analyzing 18 histologic photographs in total.

The biopsies were analyzed using hematoxylin and eosin, Masson-trichrome, and immunohistochemistry for matrix metalloproteinase (MMP)-1. Image analysis of the sectioned slides was done using ImageJ image analysis software (<http://rsb.info.nih.gov/ij/>). The dermal-epidermal junction length was measured in a 3-mm punch tissue sample. The quantity of collagen, the fibroblast count, and the number of fibroblasts with MMP-1 staining were measured in the papillary dermis.

Statistical Analyses

Statistical analyses were performed using SPSS for Windows (SPSS Inc., Chicago, IL). Before-and-after treatment comparisons were performed using the parametric *t*-test for paired samples. The statistical tests were two-sided, and a probability value of

less than 5% was considered statistically significant. The differences in the degree of improvement and percentage improvement between groups were compared using an independent sample *t*-test.

Results

All subjects completed the study. The group treated with the PRP and fractional laser combination (*n* = 11) had a mean age of 43.9 ± 7.3 (range: 30–56). The group treated with fractional laser only (*n* = 11) had a mean age of 43.6 ± 4.5 (range: 38–50).

Subjective Satisfaction Scale

One hundred percent of the group that received combination treatment and 58% of the group that received fractional laser treatment alone reported improvement in skin texture or fine wrinkles (Figure 1); 92% and 67%, respectively, reported improvement in skin elasticity; 25% and 0%, respectively, reported improvement in skin texture, and 8% and 0%, respectively, reported an increase in skin elasticity.

Objective Clinical Assessment

The improvement score for overall appearance of the face was 1.73 for the group that received combination treatment and 1.18 for the group that received fractional laser treatment alone (Figure 2). Two blinded reviewers felt that five of 11 (45%) in

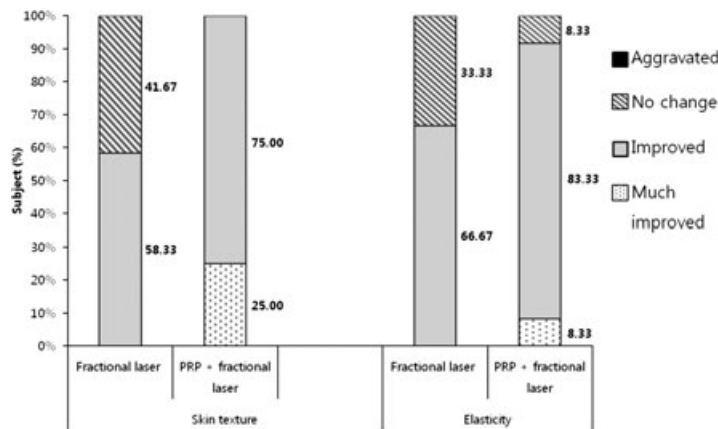


Figure 1. Subjective satisfaction scale of improvement in skin texture and elasticity.

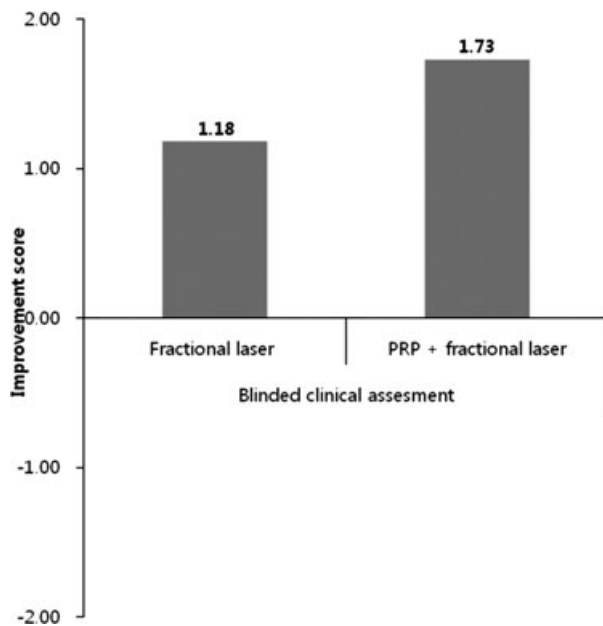


Figure 2. Blindly assessment of improvement score by comparing the baseline photograph with the final photograph.

the fractional group and eight of 11 (73%) in the combined PRP group improved. The difference between the two groups was not statistically significant.

Biophysical Analysis

Skin Surface Roughness Skin surface roughness decreased statistically significantly (from 37.2 ± 3.1 to 34.3 ± 2.3 ; 7.5%) in the group that received fractional laser treatment alone and more significantly in the group that received combination treatment (from 34.1 ± 2.9 to 30.4 ± 2.3 ; 10.3%). The difference between the two groups was not statistically significant.

Elasticity Gross skin elasticity increased from 0.77 ± 0.03 to 0.82 ± 0.03 (10.3%) in the group that received fractional laser treatment alone and from 0.78 ± 0.03 to 0.86 ± 0.03 (6.4%) in the group that received combination treatment. The increase in the former group was approximately twice as high as the increase in the latter group. The difference of elasticity between the two groups was statistically significant ($p = .004$).

Hydration Hydration increased from 53.0 ± 3.6 to 63.9 ± 3.4 in the group that underwent fractional laser treatment alone and from 54.6 ± 4.1 to 66.6 ± 4.1 in the group that underwent a combination of laser and PRP. There was no significant difference between the two groups.

Comparison of Adverse Reactions

No serious or persistent side effects occurred during the course of the study, and no subjects withdrew from the study because of an adverse event. No hypopigmentation or hypertrophic scarring was observed in any subject throughout the study period.

The pain score was 1.38 ± 0.55 for the fractional laser treatment group and 1.27 ± 0.57 for the combination treatment group. There was no significant difference between the groups.

The subjective erythema scale immediately after treatment was 2.83 ± 0.99 in the group that received combination treatment and 2.94 ± 1.01 in the group that received fractional laser treatment alone. There was no significant difference between the two groups. The duration of erythema was 1 day or less in 83% and 2 to 3 days in 17% of both groups. The E-index determined using a pectrometer (1 month after the last treatment) decreased from 8.4 ± 0.9 to 7.1 ± 0.9 in the group that received combination treatment and from 8.0 ± 0.8 to 7.9 ± 0.9 in the group that received fractional laser treatment alone. Only the decrease in the E-index in the former group was statistically significant ($p = .005$). The M-index decreased from 32.9 ± 1.5 to 31.1 ± 1.4 in the group that received combination treatment and from 31.1 ± 1.3 to 31.3 ± 1.3 in the group that received fractional laser treatment only. There was no significant difference between the two groups.

Postinflammatory hyperpigmentation or aggravation of melasma occurred in 17% of subjects ($n = 2$) in both groups. Three subjects (25%) in

the group that received combination treatment and two (17%) in the group that received fractional laser treatment alone reported that their melasma had improved. One subject treated with fractional laser alone noted an acneiform eruption that resolved completely within 1 week of treatment. Another subject treated with fractional laser only complained of skin dryness.

Histologic Analysis

In both groups, stratum corneum thickness increased, epidermal thickness decreased, and the length of the dermal–epidermal junction increased after treatment. (Figure 3, Table 1). The length of

the dermal–epidermal junction showed a more significant increase in the group that received combination treatment than in the group that received fractional laser treatment alone. The dermal thickness of the group that received fractional laser treatment alone decreased 6.0%, and the dermal thickness of the group that received combination treatment increased 15.6%. The number of fibroblasts and the volume of collagen in the papillary dermis were greater in the group that received fractional laser treatment alone, but the number of fibroblasts and the volume of collagen in the papillary dermis were greater in the group that received combination treatment. No change was

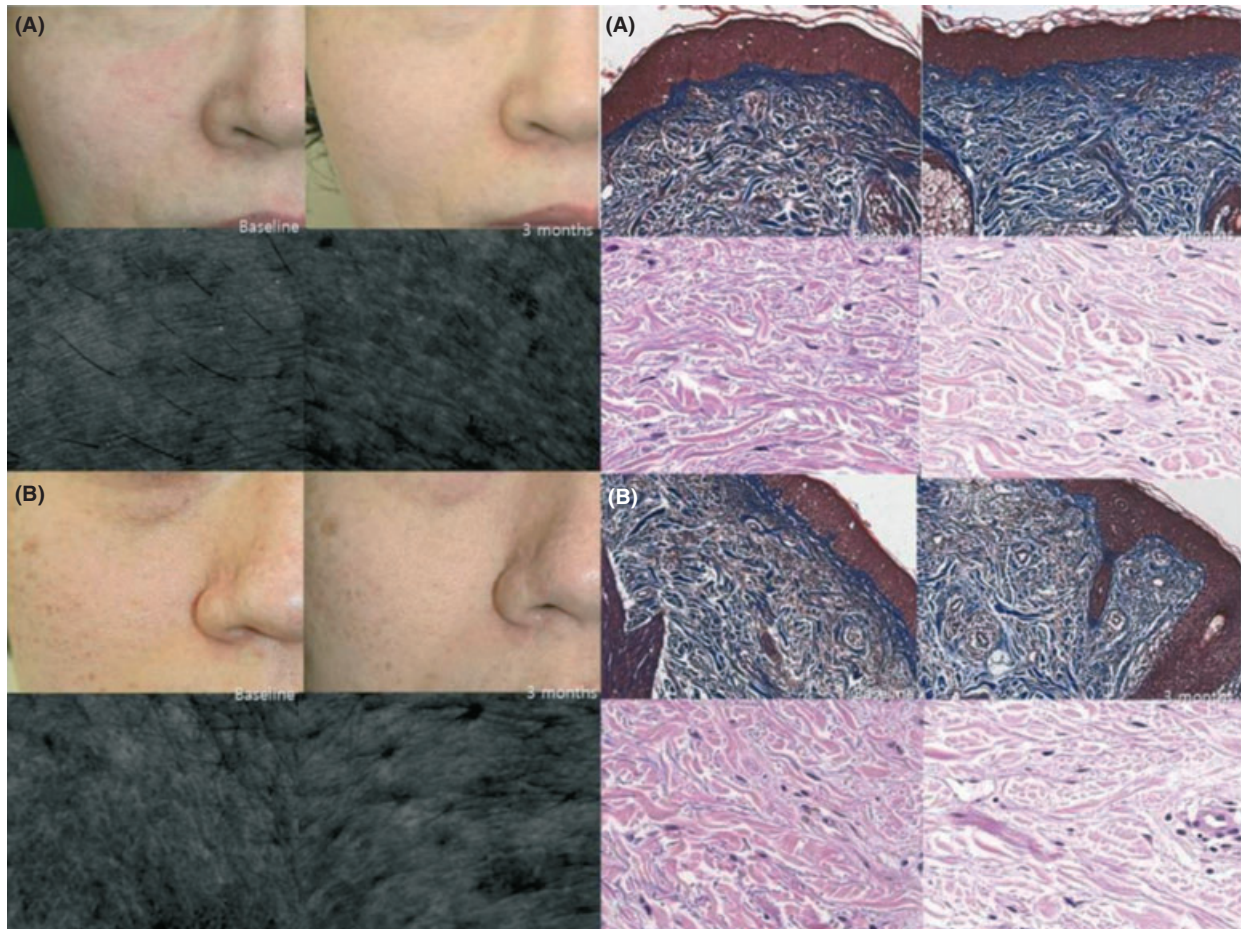


Figure 3. Examples of clinical photography and Masson-trichrome and hematoxylin and eosin staining of two subjects: (A) 50-year-old subject who underwent treatment with platelet-rich plasma combined with fractional laser, (B) 42-year-old subject treated with fractional laser alone (Masson-trichrome, original magnification $\times 40$; hematoxylin and eosin, original magnification $\times 100$).

TABLE 1. Histologic Analysis

	PRP Combined with Fractional Laser			Fractional Laser		
	Before	After	Change, %	Before	After	Change, %
Stratum corneum thickness, μm	14.2 \pm 1.8	18.0 \pm 4.5	26.7	14.8 \pm 4.1	16.8 \pm 2.6	13.7
Epidermal thickness, μm	70.4 \pm 7.5	60.8 \pm 6.1	-13.7*	71.3 \pm 10.9	59.84 \pm 4.23	-16.1
Dermal-epidermal junction length, μm^\dagger	1,655.5 \pm 85.5	2,765.1 \pm 685.0	67.0*	1,852.3 \pm 66.4	2,721.3 \pm 725.2	46.9
Dermal thickness, μm	1.93 \pm 0.50	2.24 \pm 0.64	15.6	1.90 \pm 0.02	1.79 \pm 0.25	-6.0
Average area fraction of collagen [†]	64.6 \pm 5.3	66.4 \pm 5.3	2.8	66.5 \pm 7.8	50.3 \pm 2.8	-24.3*
Number of fibroblasts/250 $\mu\text{m}^{2\dagger}$	14.8 \pm 1.0	24.4 \pm 1.6	65.4*	17.7 \pm 3.4	14.2 \pm 3.9	-19.4*
MMP-1 expression of fibroblasts/250 μm^2	7.2 \pm 0.8	9.0 \pm 2.3	24.5	5.6 \pm 1.8	6.5 \pm 2.1	17.9

Dermal-epidermal junction length was measured in a 3-mm punch tissue sample. Quantity of collagen, fibroblast count, and number of fibroblasts with matrix metalloproteinase (MMP)-1 staining were measured in the papillary dermis.

*Statistically significant difference ($p < .05$) comparing before and after treatment.

[†]Statistically significant difference between combination treatment with combination of platelet-rich plasma (PRP) and fractional laser treatment and fractional laser treatment alone.

noted in the expression of MMP-1 after treatment.

Discussion

The desire to maintain or restore a youthful appearance has become an obsession for many people. There has long been a need for effective treatments to rejuvenate the skin—treatments that should be relatively free from the risk of adverse events. Various combinations of regenerative dermatologic treatment need to be tested to increase the treatment effect and lessen adverse reactions.

There was no difference in skin surface roughness or hydration between the two groups in this study, although the group that received combination treatment had greater subjective satisfaction with skin texture and elasticity. Combination treatment with PRP and fractional laser resulted in objective improvement of skin elasticity, a lower erythema index, and an increase in collagen density as well.

The visible signs of aging facial skin are dryness, mottled red-brown dyschromia, fine wrinkling,

and coarser textural changes such as sagging and wrinkling.¹³ The histologic features of aging skin are a flattened dermal-epidermal junction, dermal atrophy, and fewer fibroblasts. Photodamaged skin is histologically characterized by disorganized collagen fibrils and elastotic degeneration. The human skin functions of cell replacement and wound healing decrease with age. In the present study, PRP treatment combined with fractional laser increased the length of the dermal-epidermal junction and the volume of collagen. Therefore, we believe that PRP has good ability to reverse photodamage by enabling controlled wound healing after laser treatment in people with poor wound healing capacity due to aging.

In addition to the many growth factors in PRP, there are other reasons why PRP works to improve aging skin. A dose-response relationship has been identified in vitro between platelet concentration and human adult mesenchymal stem cell proliferation, fibroblast proliferation, and type I collagen production.¹⁴ That study found greater proliferation of stem cells when the skin was treated with PRP or PPP activated with

calcium and thrombin than with nonactivated PRP or PPP. Hyaluronic acid draws water into the hyaluronic acid matrix, causing it to swell, which creates volume and skin turgor and lubricates tissues. There are also indications that native hyaluronic acid promotes cell proliferation and extracellular matrix synthesis and modulates the diameter of the collagen fibers. Because PRP is known to accelerate the generation of hyaluronic acid,¹⁵ it could increase skin elasticity. Additional research is needed to elucidate the therapeutic mechanism by which PRP rejuvenates skin.

This is the first study to demonstrate improvement in clinical and biophysical parameters after PRP combined with fractional laser. Subjective satisfaction, elasticity, and erythema index improved after PRP and fractional laser treatment, but objective clinical assessment and skin surface rough showed mild, statistically nonsignificant improvement.

References

1. Redaelli A, Romano D, Marciano A. Face and neck revitalization with platelet-rich plasma (PRP): clinical outcome in a series of 23 consecutively treated patients. *J Drugs Dermatol* 2010;9:466–72.
2. Sclafani AP. Platelet-rich fibrin matrix for improvement of deep nasolabial folds. *J Cosmet Dermatol* 2010;9:66–71.
3. Sclafani AP, Romo T III, Ukrainsky G, McCormick SA, et al. Modulation of wound response and soft tissue ingrowth in synthetic and allogeneic implants with platelet concentrate. *Arch Facial Plast Surg* 2005;7:163–9.
4. Hom DB, Linzie BM, Huang TC. The healing effects of autologous platelet gel on acute human skin wounds. *Arch Facial Plast Surg* 2007;9:174–83.
5. Fitzpatrick RE, Rostan EF. Reversal of photodamage with topical growth factors: a pilot study. *J Cosmet Laser Ther* 2003;5:25–34.
6. Metelitsa AI, Alster TS. Fractionated laser skin resurfacing treatment complications: a review. *Dermatol Surg* 2010;36:299–306.
7. De Paepe K, Lagarde JM, Gall Y, Roseeuw D, et al. Microrelief of the skin using a light transmission method. *Arch Dermatol Res* 2000;292:500–10.
8. Kim BJ, Lee DH, Kim MN, Song KY, et al. Fractional photothermolysis for the treatment of striae distensae in Asian skin. *Am J Clin Dermatol* 2008;9:33–7.
9. Ryu HS, Joo YH, Kim SO, Park KC, et al. Influence of age and regional differences on skin elasticity as measured by the Cutometer. *Skin Res Technol* 2008;14:354–8.
10. Koch RJ, Cheng ET. Quantification of skin elasticity changes associated with pulsed carbon dioxide laser skin resurfacing. *Arch Facial Plast Surg* 1999;1:272–5.
11. Takema Y, Yorimoto Y, Kawai M, Imokawa G. Age-related changes in the elastic properties and thickness of human facial skin. *Br J Dermatol* 1994;131:641–8.
12. Kim SD, Kim SW, Huh CH, Suh DH, et al. Changes of biophysical properties of the skin measured by non-invasive techniques after Q-switched Nd-YAG laser therapy in patients with nevus of Ota. *Skin Res Technol* 2001;7:262–71.
13. Gniadecka M, Nielsen OF, Wessel S, Heidenheim M, et al. Water and protein structure in photoaged and chronically aged skin. *J Invest Dermatol* 1998;111:1129–33.
14. Kakudo N, Minakata T, Mitsui T, Kushida S, et al. Proliferation-promoting effect of platelet-rich plasma on human adipose-derived stem cells and human dermal fibroblasts. *Plast Reconstr Surg* 2008;122:1352–60.
15. Anitua E, Sanchez M, Nurden AT, Zalduendo MM, et al. Platelet-released growth factors enhance the secretion of hyaluronic acid and induce hepatocyte growth factor production by synovial fibroblasts from arthritic patients. *Rheumatology (Oxford)* 2007;46:1769–72.

Address correspondence and reprint requests to: Nack-In Kim, MD, Department of Dermatology, College of Medicine, Kyung Hee University, #1 Hoegi-Dong, Dongdaemun-Gu, Seoul 130–702, Korea, or e-mail: nikim@khmc.or.kr