


Available online at www.sciencedirect.com

ScienceDirect

www.elsevier.com/locate/trap

Role of intra-articular platelet-rich plasma in sacroiliac joint pain

Annu Navani, MD^{a,b,*}, Deepak Gupta, BA, MS-II^c

^aDepartment of Regenerative Medicine, Comprehensive Spine and Sports Center, Campbell, California

^bDivision of Pain Medicine, Stanford University School of Medicine, Stanford, California

^cDepartment of Regenerative Medicine, Comprehensive Spine and Sports Center, Campbell, California

ARTICLE INFO

Keywords:

Sacro-iliac joint
Platelet-rich plasma
Regeneration

ABSTRACT

The goal of this case review is to evaluate safety and efficacy with the use of intra-articular platelet-rich plasma (PRP) in patients with sacroiliac (SI) joint (SIJ) pain. The secondary outcomes include additional medical treatments, hospitalization, and surgery. SIJ pain contributes significantly to the social and economic burden due to its long-standing and debilitating course. Current treatments include either interventional procedures with transient benefits or invasive surgical options. PRP has been used clinically in various settings for its anti-inflammatory and tissue repair properties attributed to growth factors. Ten patients with chronic SIJ pain who tried and failed conservative treatments were administered a single injection of 4 mm autologous PRP into the joint under fluoroscopic guidance after careful clinical and imaging evaluation. The patients were followed up at 1, 3, 6, and 12 months postinjection and primary and secondary outcomes were recorded. Verbal analog scale score for pain of all patients decreased more than 50% and their function increased for the period of 12 months. None of the patients presented to the hospital or clinic or received any treatments or surgery after the PRP injection. There were no adverse reactions, side effects, or complications. PRP presents as a promising option based on our preliminary observation. Larger, well-designed randomized controlled trials are warranted to understand the full breath of the efficacy, risks, and complications from the use of PRP for SIJ pain.

© 2016 Elsevier Inc. All rights reserved.

Introduction

Low back pain is the greatest contributor of disability worldwide and a significant burden to society being responsible for an estimated 83 million years lived with disability in 2010.^{1,2} In those with low back pain, the prevalence of sacroiliac (SI) joint (SIJ)-mediated pain ranges from 13%–30%.³ There is an even higher prevalence in patients who have had lumbar fusion surgery, with one study showing 35%

of patients with back pain after a technically successful fusion exhibiting SIJ-mediated pain.³ The vast prevalence of SIJ mediated pain is responsible for the increase in SIJ interventions from 46,940 in 2000 to 231,800 in 2008 thereby raising the combined Medicare payments for low back interventions from \$362 million in 2000 to \$1.231 billion to 2008.⁴ There is an immediate need for long-lasting, minimally invasive and cost-effective treatments for SIJ-mediated pain.

*Correspondence to: Annu H. Navani, MD, Medical Director, Comprehensive Spine and Sports Center, 3425 South Bascom Avenue, Suite 200, Campbell, California 95008.

E-mail address: anavani@cssctr.com (A. Navani).

Regenerative medicine is a rapidly growing field with a promise for tissue repair and restoration. The benefits of this field extend to a number of medical disciplines, including cardiology, neurology, vascular, plastic surgery, orthopedics, and spine. The use of biologics for low back pain has been previously described in discs, facet joints, lumbar ligaments and muscles, and epidural space. To our knowledge there have been no reported cases of intra-articular injection of platelet-rich plasma (PRP) injection for SIJ pain. In this article we have discussed safety and efficacy with the use of intra-articular PRP for SIJ-mediated pain.

Biologics background

There are several autologous and allogenic biologic preparations from a variety of sources such as fetal, embryonic, amniotic, adult skin, peripheral blood, adipose tissue, and bone marrow. The autologous products, PRP, obtained from centrifugation of human peripheral blood and the mesenchymal stem cells from human adipose tissue or bone marrow are most commonly used in clinical practice.

PRP is the plasma fraction rich in platelets that package a variety of growth factors in their alpha granules, which along with cytokines modulate the anti-inflammatory pathway and ultimately decrease inflammation and repair the damaged tissue. PRP has been shown to promote macrophage activation, collagen proliferation, cellular differentiation, vasodilation, and vascularization. The rationale behind the injection of PRP is to deliver a high concentration of autologous growth factors, and cytokines to areas with poor vascularization or poor inherent healing potential.⁵ This makes it a worthwhile solution for SIJ related inflammation and pain.

Clinical presentation

The SIJ is the largest axial joint in the human body. It is weight bearing, diarthrodial synovial joint that transfers energy, and force from the spine to the pelvis.⁶⁻⁸ A healthy SIJ is stabilized by the SI, iliolumbar, sacrotuberous, and sacrospinal ligaments.⁷ The specific innervation of SIJ is controversial.⁹ The innervation from the ventral rami of L4, L5, the dorsal rami of L5, S1, and S2 is most commonly accepted. SIJ-mediated pain can be caused by osteoarthritic degeneration, inflammatory disease, tumor, infection, or disruption of the joint, which can occur via trauma or pregnancy.¹⁰ Pain from the SIJ most commonly presents in the gluteal region, but can be referred to a variety of other sites, including the lumbar region, abdomen, groin, lower limbs, and foot.⁶

Diagnosing SIJ-mediated pain can be difficult because the presenting pain is similar in both character and location to other sources of back pain.^{6,7} Imaging studies such as X-rays, computed tomography or magnetic resonance imaging do not

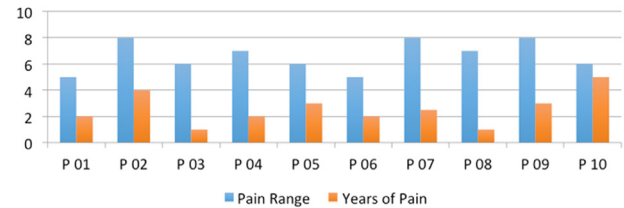


Fig. 1 – Pain range (VAS) and years of pain distribution. VAS, visual analog scale. (Color version of figure is available online.)

serve as a conclusive diagnostic tool except in case of significant structural joint alteration. The current assessment for diagnosing SIJ-mediated pain is single or double diagnostic block of the heavily innervated SIJ through the injection of local anesthetic. The 2013 American Society of Interventional Pain Physicians (ASIPP) guidelines describe the evidence for single or double blocks with 75%-100% pain relief as good.¹¹ To help clinicians decide which patients warrant further study and diagnostic blocks, provocative maneuvers, including the distraction, compression, thigh thrust, Gaenslen's and sacral thrust test, can be useful if three or more are positive.^{6,11}

Current treatments

As with most musculoskeletal conditions, conservative and interventional management options are available for SIJ-mediated pain. Conservative options include exercise therapy and chiropractic manipulation, but no high-quality evidence supports their efficacy.¹⁰

Nonsurgical interventions to manage SIJ-mediated pain are intra-articular and peri-articular injections as well as neurolysis of the SIJ. The efficacy of intra-articular steroid injections has been evaluated in many clinical and systematic reviews, but the evidence for the effectiveness is limited for short- and long-term relief.¹¹ ASIPP guidelines recognize the effectiveness of conventional radiofrequency neurotomy of SIJ

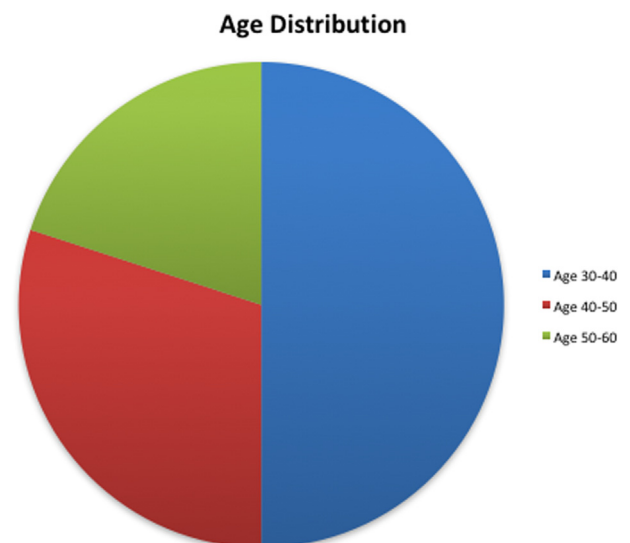


Fig. 2 – Age distribution of patients, years. (Color version of figure is available online.)

Table 1 – Age distribution categorized by age groups.

Age range	30-40	40-50	50-60
Number of patients	5	3	2

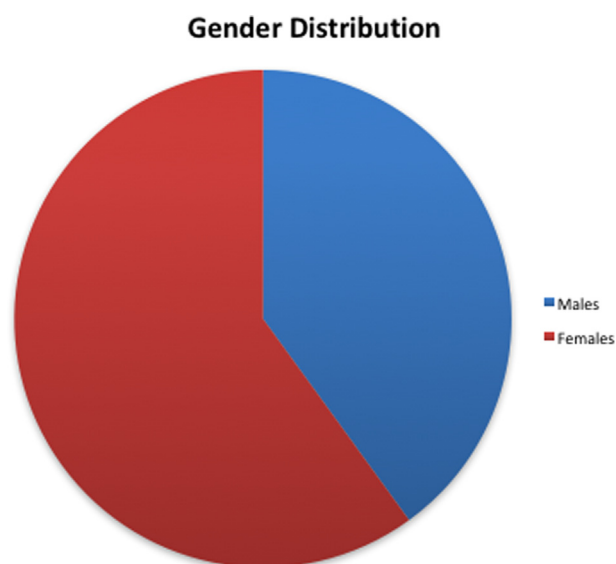


Fig. 3 – Gender distribution of patients. (Color version of figure is available online.)

innervation as limited.¹¹ In fact, the only therapy described by ASIPP to have a better than limited efficacy was cooled radiofrequency neurotomy.¹¹

Methods

Given the lack of effective, long-term solutions for SIJ pain, we have offered PRP injections to patients with SIJ pain from inflammatory or degenerative pathology. In this report, we share our observation of pain and functional outcomes from this therapy.

Ten patients, 4 males, and 6 females who suffered from SIJ-mediated pain of >6 months duration were treated with PRP. The age distribution included 5 patients below age of 40 and 5 over 40-year old (Table 1 and Figures 1-3).

They had tried and failed conservative treatments including physical therapy and NSAIDs. They had at least 1 positive provocative test and reported diagnostic response of >50% after of local anesthetic injection consistent with the duration of action. The inclusion and exclusion criteria was as presented in Table 2.

Magnetic resonance imaging of the SIJs was reviewed for all patients for identification of inflammation with presence of edema in subchondral bone and bone marrow and surrounding ligaments or degenerated when structural changes such

as erosions, sclerosis, ankylosis were noted. In 8 cases, the imaging study was noted to be normal, 2 cases sclerotic changes were associated with concurrent presence of edema.

The procedure including risks and benefits were explained in details to each patient. After informed consent, the patients underwent unilateral or bilateral SIJ injections, depending on their symptoms under fluoroscopy guidance in an operating room setting using aseptic precautions. Approximately 20-30 degrees of contralateral obliquity along with 5-10 degrees of cephalocaudal tilt revealed the target site, identified as the zone of maximum radiolucency. A 22-gauge 3.5 or 5-in. needle depending on the depth of the joint was advanced under fluoroscopic guidance until the needle contacted the sacral lamina and then walked off laterally into the joint and give away sensation was experienced. The final needle position was confirmed in anteroposterior, oblique and lateral view of the fluoroscopy.

PRP was obtained using 60 mL of whole blood to yield 7 mL of PRP using the EmCyte Corporation centrifuge with double spin technique at 3800 rpm for 1.5 minutes in the first cycle followed by 5 minutes in the second. Approximately 4 mL of PRP was injected into each joint until increased pressure was felt in the plunger and solution could not be injected easily (Figures 4 and 5). No activating or additive agents were used with PRP. After the injection, the patients were observed in the recovery room for 30 minutes and then discharged home in stable condition with detailed postoperative instructions. They were followed per protocol at 1 month, 3 months, 6 months, and 12 months postinjection. Postoperative instructions included 2 weeks of limited activity with bracing followed by progressive SIJ stabilization and mobilization exercises until they reached their full functional potential.

Results

All patients improved by 3 months postinjection and maintained low pain levels not requiring any additional treatments for up to 6 months postinjection. SF-36 demonstrated improvement in both physical component summary scores and mental component summary (MCS) scores in all patients. There were no adverse reactions or complications in any patient. None of the patients presented to the emergency room, get hospitalized or receive surgery or any other interventions for the SIJ pain.

The results of changes in visual analog scale, SF-36 (physical component summary and mental component summary) changes at the 1, 3, 6, and 12-month follow-up are presented in Figures 6-8.

Table 2 – Inclusion and exclusion criteria for participation.

Inclusion criteria	Exclusion criteria
SIJ-mediated low back pain for ≥ 6 months	Patient refusal
Failure of conservative treatment measures	Presence of a known bleeding disorder
One or more diagnostic or therapeutic SIJ injection with LA \pm steroids with >50% relief	Pregnancy
	Systemic or local infection
	Presence of an unstable medical or psychiatric condition
	Other significant low back pain generator

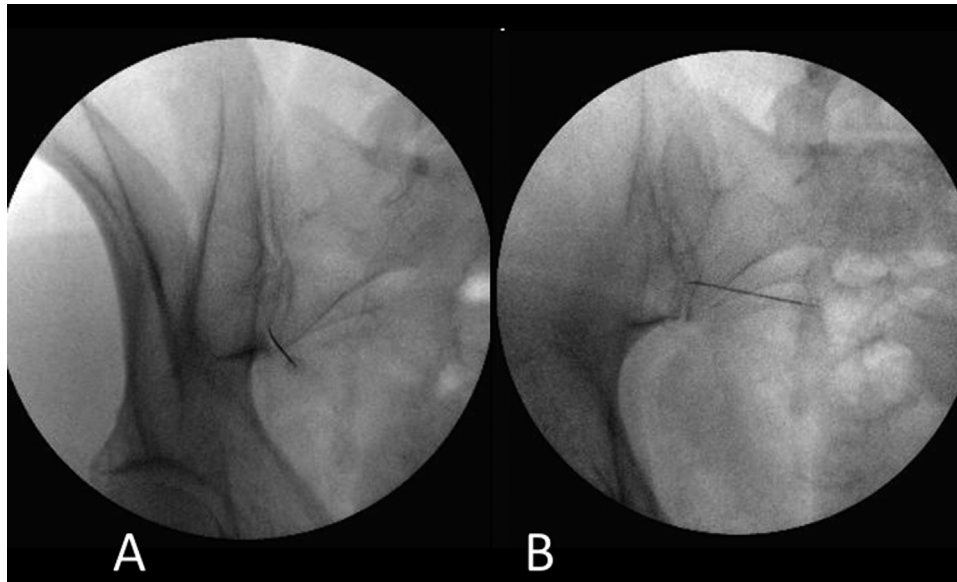


Fig. 4 – Left sacroiliac joint; contralateral oblique view at 20° (A) and 7° (B) with needle tip in between the posterior and anterior joint lines.

Discussion

PRP has been extensively studied in spine and orthopedics in context of intervertebral disc degeneration, spinal fusion, and osteoarthritis and cartilage repair of major joints. Despite its extensive use in major joints, there have been no reports of its use in sacroiliac joints. There is extensive literature on prolotherapy over the sacroiliac ligaments including a recent case study of four patients with series of 2 PRP injections via prolotherapy technique at the Hackett points A-C under ultrasound guidance.¹² The study by Ko et al¹² reported statistically significant reduction in pain, and improvement in quality of life at 12 months and at follow up 4-years posttreatment. The PRP injection, however, was injected at the ligament bone junction at the Hackett points A-C and

not injected directly into the joint. Here, we have discussed the results in the first ever reported use of intra-articular SIJ PRP.

The essence of PRP is to boost the damaged tissue's own repair processes by delivering a concentrated dose of autologous growth factors and thereby activating local mesenchymal stem cells at the site of injury. Some of the specific growth factors released such as platelet-derived growth factor, transforming growth factor-beta 1, insulin-like growth factor-1, vascular endothelial growth factor, fibroblastic growth factor, epidermal growth factor have been shown to control the mechanism of tissue repair and restoration.¹³ Through carefully orchestrated chemotaxis, angiogenesis, cellular migration, proliferation and differentiation and extra cellular matrix production, regeneration is brought forth.¹⁴

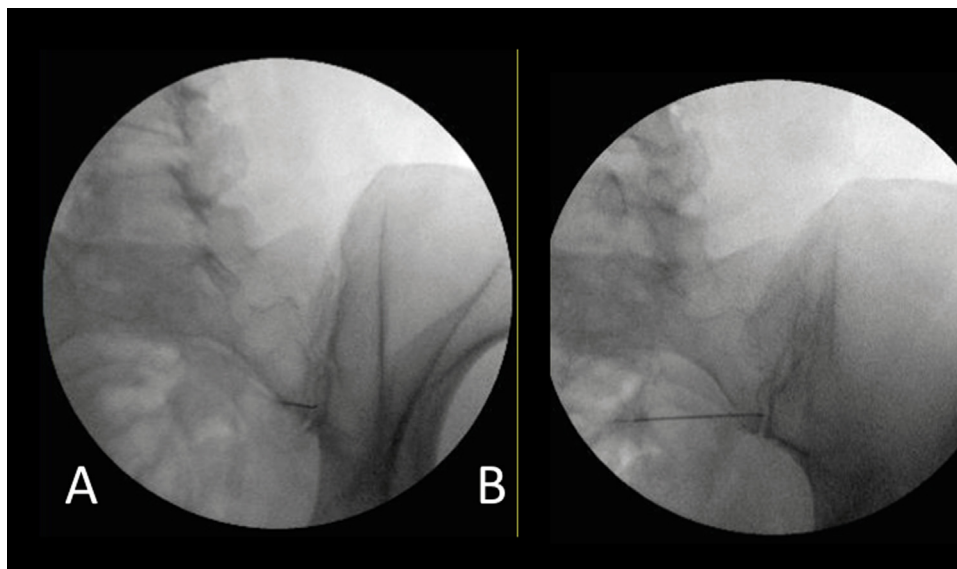


Fig. 5 – Right sacroiliac joint; contralateral oblique view at 22° (A) and 5° (B) with needle tip in between the posterior and anterior joint lines. (Color version of figure is available online.)

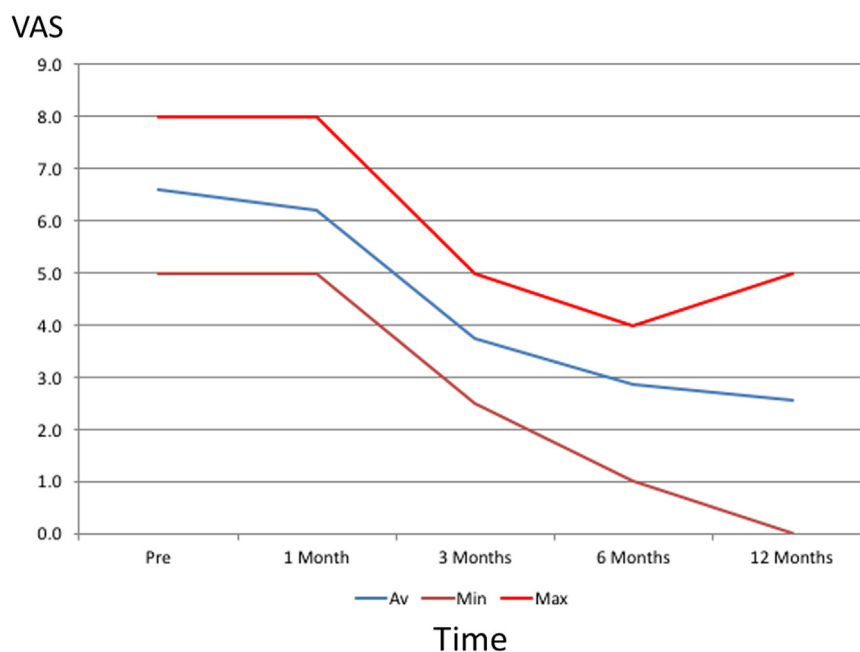


Fig. 6 – Changes in VAS score for minimum, average, and maximum VAS along y-axis and time interval along x-axis. VAS, visual analog scale. (Color version of figure is available online.)

This process seems particularly relevant in the setting of inflamed or degenerated SIJ-mediated pain.

Similarly to PRP therapy, there is a breadth of evidence supporting the use of MSCs in musculoskeletal, orthopedic, and spine conditions. MSCs are self-renewing and undifferentiated and upon induction by certain growth factors, these cells can differentiate into osteoblast, chondroblasts, and adipocytes.¹⁵ They have demonstrated secretion of growth factors, cell proliferation, angiogenesis, anti-inflammatory effects, antiapoptotic effects, and immunomodulation. The

exploitation of these properties has shown promise in regenerating the tissue of degenerated IVDs through increased proteoglycan synthesis and type II collagen production¹⁶ and providing pain relief.¹⁷ There are no published reports on the use of bone marrow concentrate for SIJ-mediated pain to our knowledge. Our preliminary results of safety and efficacy with intra-articular SIJ bone marrow concentrate look promising.

Based on our observation earlier, PRP appears to be an assuring option for SIJ mediated pain. This is noted improvement in pain and function in patients with chronic SIJ pain

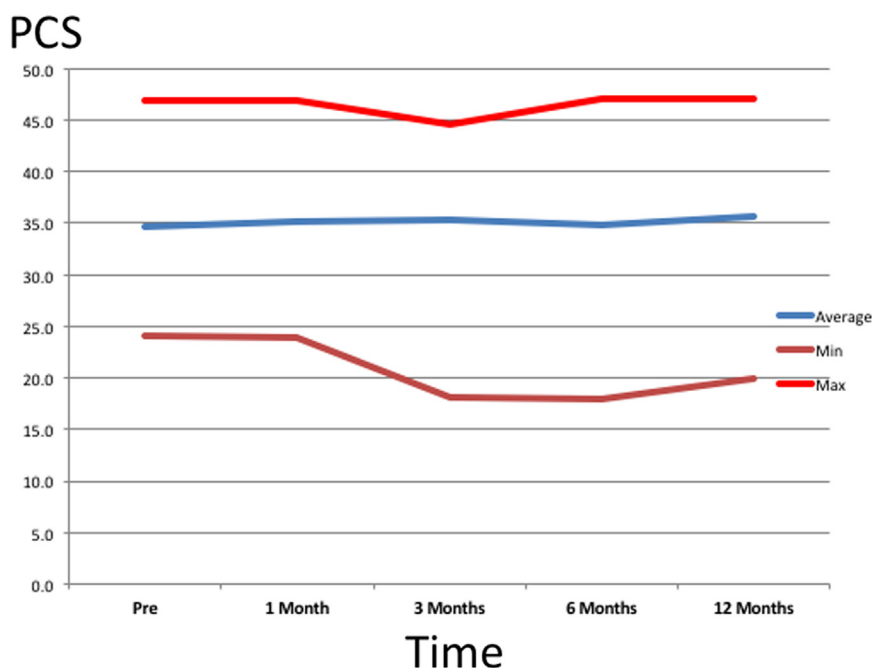


Fig. 7 – Changes in SF-36 PCS for minimum, average, and maximum PCS along y-axis and time interval along x-axis. PCS, physical component summary scores. (Color version of figure is available online.)

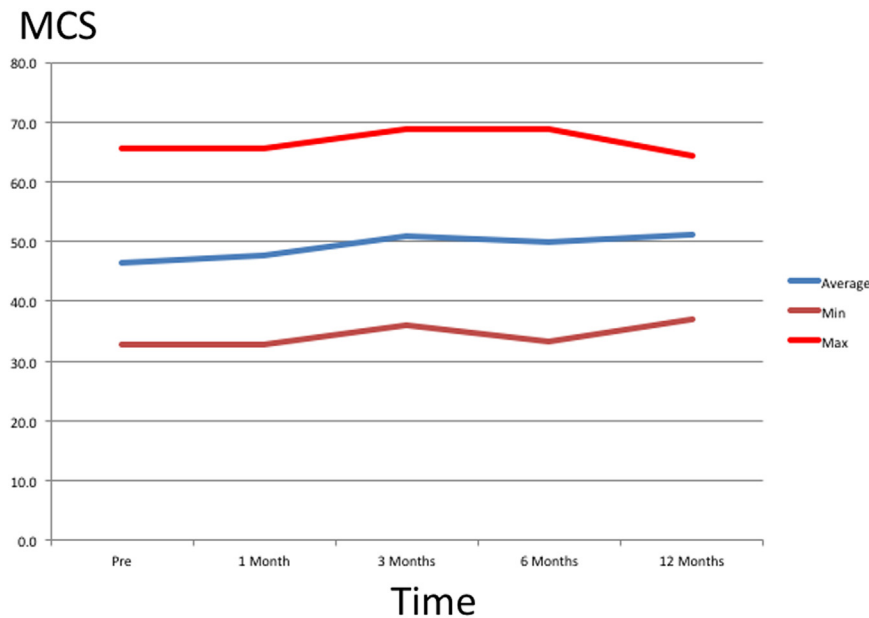


Fig. 8 – Changes in SF-36 MCS for minimum, average, and maximum with MCS along y-axis and time interval along x-axis. MCS, mental component summary scores. (Color version of figure is available online.)

for as long as 8 years at various points along the spectrum of SIJ inflammation and degeneration. We recognize the shortcomings of our report including the small sample size and short duration of observation; however, this does provide an inaugural consideration for biologics for SIJ mediated pain. Larger well-designed, randomized clinical trials are needed to understand the full effect of PRP and bone marrow concentrate for SIJ-mediated pain.

Conclusion

SIJ is a strong contributor of low back pain, the number one cause of disability in United States. Currently available interventional and surgical therapeutic options are not sufficient for long-term pain relief. We report the first case series of intra-articular use of PRP for SIJ-mediated pain. PRP provides a natural, nonpharmacological, minimally invasive option that has the potential for repair and restoration. There is need for larger well-designed randomized controlled studies to understand the full breath of its application to SIJ-mediated pain.

REFERENCES

- Buchbinder R, Blyth F, March L, Brooks P, Woolf A, Hoy D. Placing the global burden of low back pain in context. *Best Pract Res Clin Rheumatol*. 2013;27(5):575–589.
- Hoy D, March L, Brooks P, et al. The global burden of low back pain: estimates from the Global Burden of Disease 2010 study. *Ann Rheum Dis*. 2014;73(6):968–974.
- Boswell MV, Trescot AM, Datta S, et al. Interventional techniques. Evidence-based practice guidelines in the management of chronic spinal pain. *Pain Phys*. 2007;10(1):7–111.
- Shaffrey C, Smith J. Nonoperative care to manage the sacroiliac joint. *J Neurosurg Spine*. 2014;20(4):351–352.
- Tuakli-Wosornu Y, Terry A, Lutz G, et al. Original Research—CME: lumbar intradiscal platelet-rich plasma (PRP) injections: a prospective, double-blind, randomized controlled study. *PM&R*. 2016;8:1–10.
- Vanelderen P, Szadek K, Van Zundert J, et al. Sacroiliac joint pain. *Pain Pract*. 2010;10(5):470–478.
- Dreyfuss P, Dreyer S, Cole A, Mayo K. Sacroiliac joint pain. *J Am Acad Orthop Surg*. 2004;12(4):255–265.
- Hoek van Dijke G, Snijders CJ, Stoeckart R, Stam H. A biomechanical model on muscle forces in the transfer of spinal load to the pelvis and legs. *J Biomech*. 1999;32(9):927–933.
- Forst S, Wheeler M, Fortin J, et al. The sacroiliac joint: anatomy, physiology, and clinical significance. *Pain Phys*. 2006;9(1):61–68.
- Polly D, Cher D, Sembrano J, et al. Randomized controlled trial of minimally invasive sacroiliac joint fusion using triangular titanium implants vs nonsurgical management for sacroiliac joint dysfunction: 12-month outcomes. *Neurosurgery*. 2015;77(5):674–690.
- Manchikanti L, Abdi S, Atluri S, et al. An update of comprehensive evidence-based guidelines for interventional techniques in chronic spinal pain. Part II: Guidance and recommendations. *Pain Phys*. 2013;16(suppl 2):S49–S283.
- Ko G, Mindra S, Lawson G, Whitmore S, Arseneau L. Case series of ultrasound-guided platelet-rich plasma injections for sacroiliac joint dysfunction. *J Back Musculoskeletal Rehabil*. 2016:1–8.
- Wang S, Rui Y, Tan Q, Wang C. Enhancing intervertebral disc repair and regeneration through biology: platelet-rich plasma as an alternative strategy. *Arthritis Res Ther*. 2013;15(5):220.
- Bennett N, Schultz G. Growth factors and wound healing: biochemical properties of the growth factors and their receptors. *Am J Surg*. 1993;165(6):728–737.
- DePalma M, Gasper J. Regenerative medicine: cellular supplementation technologies for painful spine disorders. *PM&R*. 2015;7(4):S19–S25.
- Vasiliadis E, Pneumaticos S, Evangelopoulos D, Papavassiliou A. Biologic treatment of mild and moderate intervertebral disc degeneration. *MolMed*. 2014;20:400–409.
- Pettine K, Suzuki R, Sand T, Murphy M. Treatment of discogenic back pain with autologous bone marrow concentrate injection with minimum two year follow-up. *Int Orthop*. 2016;40(1):135–140.